

## Dentofacial Changes after Orthodontic Intervention with Eruption Guidance Appliance in the Early Mixed Dentition

Katri Keski-Nisula<sup>a</sup>; Leo Keski-Nisula<sup>b</sup>; Hannu Salo<sup>c</sup>; Kati Voipio<sup>d</sup>; Juha Varrela<sup>e</sup>

### ABSTRACT

**Objective:** To evaluate skeletal and dentoalveolar changes induced by the eruption guidance appliance in the early mixed dentition.

**Materials and Methods:** Pre- and posttreatment cephalometric radiographs of 115 consecutively treated children, 62 boys and 53 girls, were compared with those obtained from a control group of 104 children, 52 boys and 52 girls. Pretreatment radiographs were taken at the deciduous-mixed dentition interphase (T1) and after full eruption of all permanent incisors and first molars (T2). The mean age of the children in both groups was 5.1 years at T1 and 8.4 years at T2.

**Results:** A significant difference between the groups at T2 was found in the mandibular length, midfacial length, and maxillomandibular differential. The increase in mandibular length was 11.1 mm in the treatment group and 7.2 mm in the control group. No differences were found in measurements of maxillary position or size. There was a significant shift toward a Class I relationship in the treatment group. Labial tipping and linear protrusion of the mandibular incisors was evident in the treatment group at T2. There was no effect on the inclination or position of the maxillary incisors.

**Conclusions:** Occlusal correction was achieved mainly through changes in the dentoalveolar region of the mandible. In addition, the appliance enhanced condylar growth resulting in a clinically significant increase in mandibular length. No effect was observed on maxillary position, maxillary size, inclination or protrusion of the maxillary incisors, or facial height.

**KEY WORDS:** Early treatment; Eruption guidance appliance; Cephalometry

### INTRODUCTION

Large individual variation in children's growth patterns and growth potential is usually considered to favor an individualized approach in orthodontic therapy. However, attempts have been made to apply more

generalized interceptive measures in the community to reduce or eliminate malocclusion.<sup>1,2</sup>

Väkiparta et al<sup>2</sup> studied the effects of an early treatment oriented orthodontic program for which a systematic screening at the age of 8 years was followed by early interceptive treatment. Examination of the children at the age of 12 years showed that the treatment need was significantly reduced. Al Nimri and Richardson<sup>1</sup> investigated the effectiveness of an interceptive program that targeted selected unfavorable features of the developing occlusion and showed that the change in the dental health component of the Index of Orthodontic Treatment Need (IOTN) was significantly greater in the treated children compared to the controls.<sup>1</sup>

Neither of the studies cited above<sup>1,2</sup> included Class II occlusion or Class II tendency to select children in the interceptive program. This seems to be in line with the recent findings suggesting that only minor benefits can be obtained by early treatment in Class II patients.<sup>3-6</sup> However, other studies have reported considerably better results after an early intervention.<sup>7-9</sup> A recent clinical trial investigated the occlusal effects of

<sup>a</sup> Chief Orthodontist, Vaasa Central Hospital, Vaasa, Finland.

<sup>b</sup> Assistant Professor, Department of Radiology, Tampere University Hospital, Tampere, Finland.

<sup>c</sup> Chief Dental Officer, Jalasjärvi Health Center, Jalasjärvi, Finland.

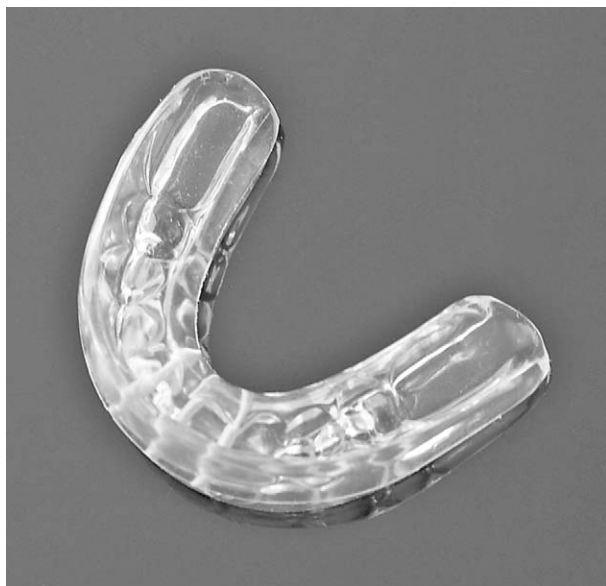<sup>d</sup> General Practitioner, Kurikka Health Center, Kurikka, Finland.

<sup>e</sup> Professor and Department Chair, Department of Oral Development and Orthodontics, University of Turku, Turku, Finland.

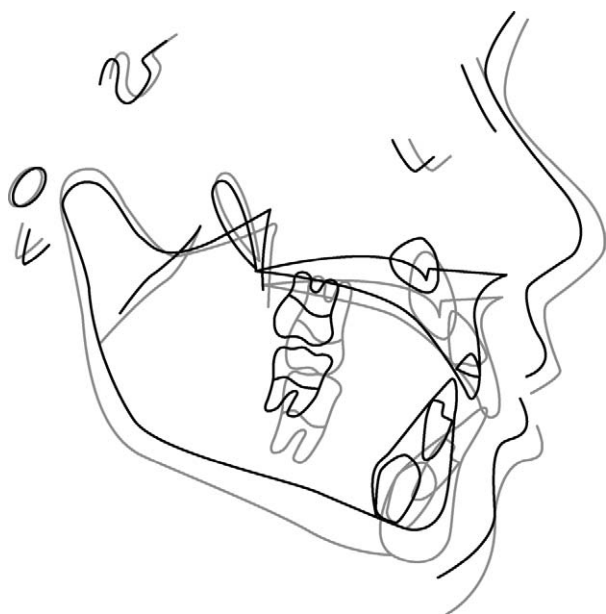
Corresponding author: Dr Juha Varrela, Institute of Dentistry, University of Turku, Lemminkäisenkatu 2, FIN-20520 Turku, Finland (e-mail: juha.varrela@utu.fi)

Accepted: May 2007. Submitted: January 2007.

© 2008 by The EH Angle Education and Research Foundation, Inc.

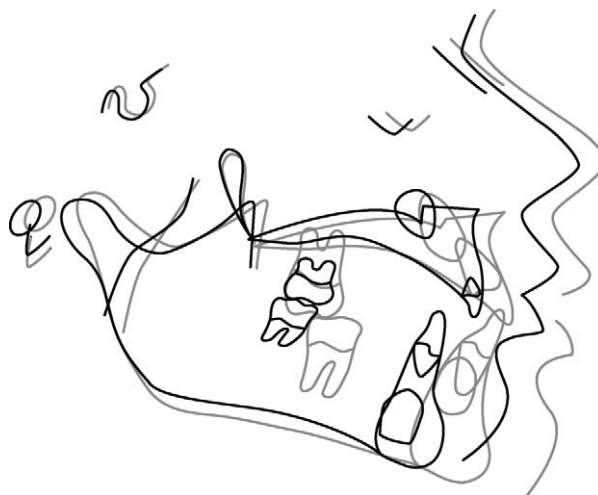

**Figure 1.** Prefabricated eruption guidance appliance (Occluso-Guide, Ortho-Tain Inc).



**Figure 2.** Treated child (EK) before (5.1 years) and after (8.4 years) treatment with eruption guidance. Superimposition on Frankfort horizontal at pterygoid verticale.

the eruption guidance appliance.<sup>9</sup> Complete age cohorts of children were screened in the deciduous dentition, and orthodontic intervention with the eruption guidance appliance was carried out in the mixed dentition in children showing a tendency to Class II occlusion, crowding, increased overjet or overbite with lack of tooth-to-tooth contact between the incisors, anterior crossbite, and/or buccal crossbite (scissors bite). A comparison with an untreated control group with similar malocclusions revealed that an efficient Class II



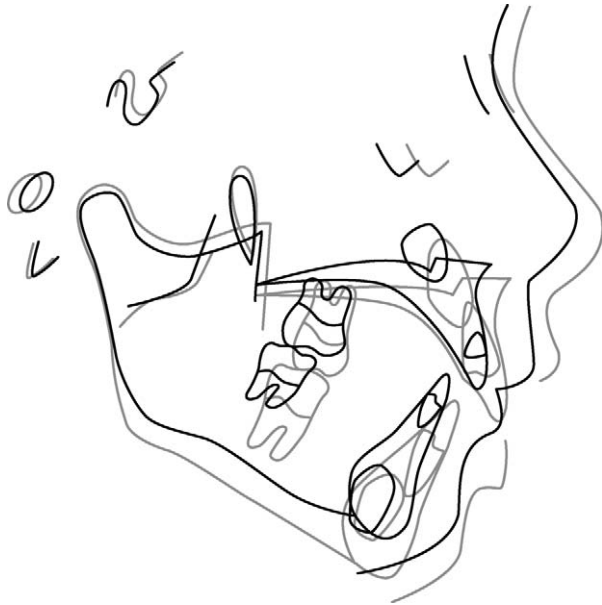
**Figure 3.** Treated child (JT) before (6.1 years) and after (8.9 years) treatment with eruption guidance. Superimposition on Frankfort horizontal at pterygoid verticale.

correction, along with a general normalization of the occlusal development, was achieved in the majority of the patients.<sup>9</sup>

The purpose was to cephalometrically analyze craniofacial and dentoalveolar morphology in children who had undergone orthodontic intervention with the eruption guidance appliance in the early mixed dentition.

## MATERIALS AND METHODS

The study population was collected from three rural municipalities in western Finland: Jalasjärvi, Kurikka, and Seinäjoki. The treatment sample of 115 children was derived from the 1992 and 1993 age cohorts in Jalasjärvi and from the 1992 age cohort in Kurikka. All children in these age cohorts were screened during the late deciduous dentition period, and those diagnosed as needing treatment received a full clinical examination at the onset of the mixed dentition period.<sup>10</sup> Children were included in the treatment group if they showed one or more of the following occlusal characteristics: (1) distal step ( $\geq 1$  mm), (2) Class II canine relationship ( $\geq 1$  mm), (3) excess overbite ( $>3$  mm and lack of tooth-to-tooth contact between the incisors), (4) deep bite ( $>3$  mm with gingival contact of the incisors), (5) crowding, (6) anterior crossbite, and (7) scissors bite (buccal crossbite). The treatment group was treated using the eruption guidance appliance only (Figure 1). Children who had a moderately or severely constricted maxilla or a skeletal Class III relationship were first treated with an expansive arch and/or face-mask. These children as well as those who refused the treatment or did not cooperate were excluded from the present analyses.<sup>9</sup> The mean active treatment time was 3.3 years (range 5.1 to 8.4 years).



**Figure 4.** Control child (AJ) at T1 (6.3 years) and T2 (8.1 years). Superimposition on Frankfort horizontal at pterygoid vertecale.

The control group was a random sample of 104 children from Seinäjoki (population 30,000) who fulfilled the same criteria, ie, they represented the 1992 and 1993 age cohorts, were screened during the late deciduous dentition period, and had similar occlusal deviations. The children in the control sample received a full clinical examination, including collection of dental casts and lateral cephalograms at the onset of the mixed dentition period; but their treatment was not started until the late mixed dentition in accordance with the treatment protocol that was followed in the dental clinics of Seinäjoki. The treatment and control samples were all healthy Finnish children and none had undergone orthodontic treatment previously. Children and their parents were free to decline participation in the study at any time.

The timing of the examinations and interventions was based individually on the stage of dental development of each child and not on chronologic age. Treatment was started at the beginning of the mixed dentition period, ie, when the first deciduous incisor was exfoliated (T1). Active treatment was completed after all permanent incisors and first molars were fully erupted (T2). The present investigation evaluates the skeletal changes that occurred from T1 to T2 in 115 consecutively treated children in the treatment group (62 boys and 53 girls) and 104 children in the control group (52 boys and 52 girls).

The mean age in both treatment and control groups was 5.1 years ( $SD \pm 0.5$ ) at T1 and 8.4 years ( $SD \pm 0.5$ ) at T2. During active treatment, each child wore two to three prefabricated eruption guidance appliances

of different sizes (Nite-Guide or Occlus-o-Guide, Ortho-Tain Inc).<sup>11</sup> The appliances were worn during sleeping hours only. If difficulties were encountered, daytime wear of 1 hour was recommended until the problems with night-wear disappeared.<sup>9</sup> The average duration of active treatment was 3.3 years. At point T2 all treated children entered a retention period during which the last of the appliances was used as a retainer, two nights per week. The retention was continued until all permanent canines, premolars, and second molars were fully erupted. No further treatment was normally required or planned.

The lateral cephalograms were taken with standard cephalostats.<sup>12</sup> Computer assisted analysis of the cephalograms was carried out by the first author. The landmarks and measurements used in the analysis are listed in Table 1. The cephalometric assessment was carried out as described previously.<sup>12</sup> Occlusal characteristics were measured as described earlier.<sup>10</sup> The differences between the sample means were tested with Student's *t*-test. The relationships between continuous variables were further tested with simple linear regression and correlation analysis. A *P*-value difference  $< .05$  was interpreted as statistically significant.

## RESULTS

No statistically significant differences were detected between the treatment and control groups in the occlusal or cephalometric variables at the beginning of the study (Table 2). From T1 to T2, overjet and overbite decreased in the treatment group and increased in the control group (Table 2). In the treatment group, the sagittal relationship of molars improved by 1.9 mm and the canines by 1.5 mm. In the control group, the molar and canine relationship remained virtually unchanged showing a tendency to a Class II occlusion. Differences between the groups in overjet, overbite, and molar and canine relationship were statistically significant at T2.

In most skeletal variables an equal amount of growth took place in the treatment and control children during the observation period (Table 2). In addition, the growth direction of the mandible, measured by the facial axis angle, was similar on both groups. In midfacial length, mandibular length, and maxillomandibular differential, the treatment children showed a significantly greater increase compared with the controls. In mandibular length, the growth increment was 11.1 mm in the treatment group and 7.2 mm in the control group. The greater mandibular growth in the treatment group also largely explains the difference in midfacial length and the maxillomandibular differential. The Wits appraisal was significantly smaller in the treatment

**Table 1.** Landmarks and Measurements

Points	
Nasion (Na)	Anterior limit of the nasofrontal suture
Orbitale (Or)	Lowest point on external border of orbital cavity
Porion (Por)	Most superior point of external auditory meatus
Basion (Ba)	Most inferior posterior point of occipital bone at anterior margin of occipital foramen
Sella (Se)	Midpoint of sella turcica
Anterior nasal spine (ANS)	Tip of anterior nasal spine
Posterior nasal spine (PNS)	Tip of posterior nasal spine
Pt point (Pt)	Intersection of inferior border of foramen rotundum with posterior wall of pterygomaxillary fissure
Gonion (Go)	Intersection of line connecting most distal aspect of condyle to distal border of ramus and line at base of mandible
Condylion (Co)	Most posterior-superior point on head of mandibular condyle
Pogonion (Pog)	Most anterior point on mandibular symphysis
Menton (Me)	Most caudal point in outline of symphysis, formed at intersection of mandibular plane
Gnathion (Gn)	Cephalometric landmark formed by intersection of (1) tangent of most inferior point of symphysis and most inferior point of gonial region and (2) line connecting NA and Pog
Point CC (center of cranium)	Cephalometric landmark formed by intersection of Ba-Na and Pt-Gn lines
Point A	Deepest point of curve of maxilla between ANS and dental alveolus
Point B	Deepest point of curve of mandible between Pog and dental alveolus
PM (protuberance menti or supra pogonion)	Point selected where curvature of anterior border of symphysis changes from concave to convex
XI point	Point at geographic center of ramus
AI incisor	Incisal tip of maxillary incisor
BI incisor	Incisal tip of mandibular incisor
Planes and angles	
Maxilla to cranium	Distance from Point A to NA-perpendicular (constructed by dropping line vertically inferior to An and perpendicular to Frankfort horizontal); describes sagittal position of anterior border of maxilla to cranium
Mandible to cranium	Distance from Pog to NA-perpendicular; describes sagittal position of chin in relation to cranium
Anterior cranial length	Measured from Point CC to Na along the Ba-Na plane; describes length of anterior cranial base
Convexity	Point A to plane from Na to Pog; describes sagittal relation of maxilla to mandible
Lower facial height	Angle formed by XI-ANS plane and XI-Pog plane
Condylion to point A	Describes effective midfacial length
Condylion-gnathion	Describes effective mandibular length
Maxillomandibular differential	Difference between distance from Co to Point A and distance from Co to Gn; evaluates sagittal skeletal imbalance
Menton-ANS	Describes lower anterior face height
Facial axis angle	Angle formed by Point CC-Gn plane and Ba-Na plane; describes growth direction of mandible
Mandibular plane to Frankfort horizontal	Angle formed by mandibular plane and Frankfort horizontal; describes shape mandible
PNS-ANS	Measure of maxillary length
PNS-A	Measure of maxillary length
Interincisal angle	Angle formed by long axes of maxillary and mandibular incisors
B1 to A-pogonion plane	Measured from tip of mandibular incisor to plane from Point A to Pog; describes protrusion of mandibular incisors
A1 to A-pogonion plane	Measured from tip of maxillary incisor to plane from Point A to Pog; describes protrusion of maxillary incisors
IMPA	Angle formed by long axis of mandibular incisor and mandibular plane; describes inclination of mandibular incisors
A1 to S-Na	Angle formed by long axis of maxillary incisor and Se-Na plane; describes inclination of maxillary incisors
Wits appraisal, mm	Distance between perpendicular projection from Point A to occlusal plane and perpendicular projection from Point B to occlusal plane (measured along the occlusal plane); evaluates horizontal skeletal relationship



**Table 2.** Occlusal and Cephalometric Variables in the Treatment and Control Groups at T1 and T2. The Differences Between the Groups at T1 Were Nonsignificant

	Treatment Group at T1		Control Group at T1		Treatment Group at T2		Control Group at T2		Difference Between Treatment and Control Group at T2	
	Mean	SD	Mean	SD	Mean	SD	Mean	SD	<i>P</i>	95% Confidence Interval
<b>Occlusal</b>										
Overjet (mm)	3.0	1.4	2.9	1.8	1.9	0.6	4.1	1.9	<.001	2.7 to 3.5
Overbite (mm)	3.2	1.6	3.3	1.9	2.0	1.0	4.1	1.9	<.001	1.8 to 2.6
Molar relationship (mm)	0.6	1.7	0.5	1.7	-1.3	1.0	0.4	1.9	<.001	-2.0 to 1.4
Canine relationship (mm)	1.6	1.6	1.4	1.7	0.1	0.7	1.4	1.6	<.001	-1.5 to 1.0
<b>Maxillary skeletal</b>										
A/Na-verticale (mm)	-0.7	2.6	-0.4	2.5	-1.4	3.0	-1.2	2.8	.562	-1.0 to 0.6
Condylion-A (mm)	80.6	3.9	80.8	4.7	86.3	4.3	84.7	4.5	.010	0.4 to 2.7
SNP-SNA (mm)	46.8	2.5	47.6	2.5	49.8	2.9	49.7	2.5	.931	0.7 to 0.8
SNP-A (mm)	43.8	2.4	44.5	2.2	46.1	2.9	45.9	2.4	.565	0.5 to 0.9
Anterior cranial length (mm)	54.9	3.0	55.3	3.1	54.9	3.0	55.4	3.2	.277	1.3 to 0.4
<b>Mandibular skeletal</b>										
Pogonion/NA-verticale (mm)	-9.4	4.9	-8.5	4.2	-9.0	6.5	-8.0	5.8	.260	-2.6 to 0.7
Condylion-gnathion (mm)	96.9	5.1	98.2	5.9	108.0	5.4	105.4	5.8	<.001	1.2 to 4.1
Facial axis angle (°)	92.5	3.4	92.3	3.2	91.0	3.8	91.6	3.4	.235	1.6 to 0.4
Mandibular plane/Frankfort horizontal	24.6	4.9	24.2	4.9	27.6	18.0	24.4	5.2	.089	-0.3 to 6.6
<b>Maxilla to mandible</b>										
Maxillomandibular differential (mm)	16.3	3.2	17.3	3.6	21.8	3.2	20.7	4.0	.031	0.1 to 2.1
Convexity (mm)	4.6	1.9	4.3	2.1	3.2	2.3	2.9	2.3	.449	-0.4 to 0.9
<b>Facial height</b>										
Menton-ANS (mm)	56.0	3.8	57.0	3.9	61.2	4.6	60.4	4.3	.183	-0.4 to 2.0
Lower facial height (mm)	44.8	3.9	44.3	5.8	44.4	4.2	43.6	3.8	.166	-0.3 to 1.8
<b>Incisal relationships</b>										
A1/A-Pogonion (mm)	3.7	1.7	4.0	1.9	6.7	7.6	6.5	2.3	.838	-1.4 to 1.7
B1/A-Pogonion (mm)	-0.2	2.3	-0.1	2.3	3.8	1.8	1.0	2.5	<.001	2.3 to 3.5
Interincisal angle (°)	148.6	13.9	145.0	13.9	126.2	6.8	130.7	10.8	<.001	-6.9 to -2.0
Wits appraisal (mm)	0.5	2.8	0.1	3.2	-1.9	2.4	-0.6	3.0	<.001	-2.0 to 0.5
IMPA (°)	87.8	7.5	89.7	7.3	97.0	6.0	94.0	8.1	.002	1.1 to 4.9
AI to S-Na (°)	91.7	10.5	92.7	14.2	104.1	5.6	103.7	7.9	.680	-1.5 to 2.2

group at T2, indicating a better intermaxillary relationship in comparison to the control group.

The treatment did not seem to have any effects on the protrusion or angulation of the upper incisors (Table 2). The lower incisors, on the other hand, became more protruded and more labially inclined in the treatment group. At the same time, the interincisal angle decreased.

Correlations between the occlusal characteristics at T1 and skeletal variables at T2 were analyzed in the control group where no intervention was carried out. In general, the correlations were low and of little clinical relevance. However, a moderate and statistically significant positive correlation ( $r = .4$ ,  $P < .0001$ ) was found between the width of the upper dental arch at T1 and the length of the mandible at T2. This suggests

that a narrow upper deciduous dental arch was associated with less growth of the mandible. Tracings of two treatment children and one control are shown as Figures 2, 3, and 4 respectively.

## DISCUSSION

The eruption guidance appliance has been shown to be capable to correct many aspects of the developing occlusion including overjet and overbite, openbite, spatial deficiencies, and Class II molar relationship.<sup>9,13-16</sup> The present results are consistent with earlier findings indicating that the skeletal changes induced by the eruption guidance appliance are largely restricted to the dentoalveolar region.<sup>14,15</sup> However, treatment with the eruption guidance appliance seems

to significantly enhance mandibular growth. The mandibular length, measured from condylion to gnathion, increased 3.9 mm more in the present treatment sample compared to the controls during the study period; this is equivalent to extra growth of 1.2 mm per year. Janson et al<sup>15</sup> studied a group of 30 patients who were treated with the eruption guidance appliance for 26 months and reported a similar annual enhancement in mandibular length. The present results are in agreement with the earlier findings<sup>15</sup> in that the maxillary growth is not affected. Similarly, direction of the facial growth remained unaffected.

Many studies have indicated that the growth of the mandible can be influenced by functional appliances in the middle or late mixed dentition.<sup>15,17-22</sup> The present results indicate that an orthopedic effect on mandibular growth can be achieved even earlier, in the early mixed dentition. In an analysis of treatment effects of the FR-2 appliance of Fränkel, McNamara et al<sup>18</sup> found that the growth response was greater in the older patients with a starting age of 11.5 years compared to the younger patients with a starting age of 8.5 years. The annual growth increment was 1.8 mm in the older group and 1.2 mm in the younger group.<sup>18</sup> The growth rate in the present treatment sample was 1.2 mm per year. These figures are in line with suggestions that the best response to functional therapy in terms of mandibular growth rate is achieved at or near the peak of the pubertal growth spurt.<sup>23,24</sup> However, it seems obvious that a clinically significant orthopedic effect that contributes to the correction of the Class II molar relationship can be obtained at almost any age in growing children.

The eruption guidance appliance is designed to solve crowding by expanding the dental arches.<sup>11</sup> Because a transverse deficiency of the upper dental arch is a common finding in Class II patients,<sup>25</sup> it is possible that this expansion,<sup>9</sup> in addition to the mandibular growth, enhanced the transition from a Class II to a Class I relationship. It is of interest that a moderate but significant correlation was found between the width of the upper dental arch at T1 and mandibular length at T2. This suggests that a narrow upper arch tends to restrict anterior mandibular growth in early mixed dentition.

A recent analysis of untreated Class II subjects indicated that the effect of mandibular growth that potentially could bring the lower dentition forward, seems to be lost because of intercusp locking and subsequent adaptive movements of the dentoalveolar complex.<sup>26</sup> Earlier, Johnston<sup>27</sup> suggested that the key effect of a functional appliance is to displace the mandible forward and let the condyle grow into the fossae without producing maxillary dentoalveolar compensations.

In the present study, the changes in occlusion and Wits appraisal toward a Class I relationship were significantly greater in the treatment group compared to controls. On the other hand, no differences were found in measurements that describe the position of the anterior border of the maxilla and mandible in relation to the cranium. It thus seems that a major effect of the eruption guidance appliance was indeed to induce a change in the dentoalveolar component without significantly affecting the position of the basal skeletal components. Johnston<sup>27</sup> further suggested that the forward displacement of the mandible, typical to functional appliances, would cause a relative retrusive effect on maxillary dentition. However, no such effect was evident in the present study as the maxillary dentition seemed to move forward equally in both groups. The present findings are thus in agreement with the previous results indicating that the eruption guidance appliance does not cause a significant restriction of anterior growth of maxilla.<sup>15</sup>

A significantly smaller overjet, overbite, and interincisal angle were observed in the treatment group compared to the controls at the end of the study. More pronounced labial inclination and more anterior position of the lower incisors in the treatment group seem to be the main factors that affected the incisor relationships. There seemed to be no treatment effect on inclination or protrusion of the maxillary incisors. These findings differ from those of a previous study that showed bodily protrusion, but unchanged inclination of the lower incisors and protrusion and labial inclination of the upper incisors after treatment with the eruption guidance appliance.<sup>15</sup> Linear retrusion and lingual tipping of the maxillary incisors seem to be frequent findings also with other functional appliances.<sup>18,22,28-31</sup> The different response of the incisors observed in the present study may relate to the fact that the present patients were younger and that the treatment took place during the period when the permanent incisors were erupting.

On the basis of the existing literature, Proffit<sup>31</sup> suggested that early Class II treatment is indicated only for a selected group of children. However, many studies have shown that a Class II relationship does not show spontaneous correction with growth.<sup>9,26,32-35</sup> Instead, the skeletal and occlusal features of Class II tend to become exaggerated with age. It would, therefore, be logical to seek a treatment modality that would offer a method to intercept and correct Class II development at an early stage of occlusal development. The eruption guidance appliance seems to be a promising candidate for such a purpose.<sup>9</sup> Not only Class II relationships but many other signs of disturbed occlusal development such as crowding, excess overjet,

deep bite, and openbite can be treated simultaneously with this appliance in the early mixed dentition.<sup>9</sup>

Long-term results of the present trial are not yet available, but clinical data, accumulated on the treatment effects of the eruption guidance appliance, suggest that an early intervention can produce results efficiently and consistently. After treatment and proper retention, children who have undergone early orthodontic therapy with the eruption guidance appliance do not normally require further treatment.

## CONCLUSIONS

- Occlusal correction brought about by the eruption guidance appliance was achieved mainly through changes in the dentoalveolar region of the mandible.
- Condylar growth was enhanced resulting in a clinically significant increase in mandibular length.
- No effect was observed on maxillary position, maxillary size, inclination, or protrusion of the maxillary incisors, or facial height.

## ACKNOWLEDGMENTS

This study was supported by the Finnish Dental Society Apollonia, the Medical Research Fund of Vaasa Hospital District, and Plandent Oyj.

## REFERENCES

1. Al Nimri K, Richardson A. Interceptive orthodontics in the real world of community dentistry. *Int J Paediatr Dent.* 2000; 10:99–108.
2. Väkiparta MK, Kerosuo HM, Nyström ME, Heikinheimo KA. Orthodontic treatment need from eight to 12 years of age in an early treatment oriented public health care system: a prospective study. *Angle Orthod.* 2005;75:344–349.
3. Gafari J, Shofer FS, Jacobsson-Hunt U, Markowitz DL, Laster LL. Headgear versus function regulator in the early treatment of Class II, Division 1 malocclusion: a randomized clinical trial. *Am J Orthod Dentofacial Orthop.* 1998;113:51–61.
4. Keeling SD, Wheeler TT, King GJ, Garvan CW, Cohen DA, Cabassa S, McGorray SP, Taylor MG. Anteroposterior skeletal and dental changes after early Class II treatment with bionators and headgear. *Am J Orthod Dentofacial Orthop.* 1998;113:40–50.
5. Tulloch JFC, Phillips C, Proffit WR. Benefit of early Class II treatment: progress report of a two-phase randomized clinical trial. *Am J Orthod Dentofacial Orthop.* 1998;113:62–72.
6. O'Brien K, Wright J, Conboy F, et al. Effectiveness of early orthodontic treatment with the Twin-block appliance: a multicenter, randomized, controlled trial. Part 1: Dental and skeletal effects. *Am J Orthod Dentofacial Orthop.* 2003;124: 488–494.
7. Kirjavainen M, Kirjavainen T, Hurmerinta K, Haavikko K. Orthopedic cervical headgear with expanded inner bow in Class II correction. *Angle Orthod.* 2000;70:317–325.
8. Mäntysaari R, Kantomaa T, Pirttiniemi P, Pykäläinen A. The effects of early headgear treatment on dental arches and craniofacial morphology: a report of a 2 year randomized study. *Eur J Orthod.* 2004;26:59–64.
9. Keski-Nisula K, Hernesniemi R, Heiskanen M, Keski-Nisula L, Varrela J. Orthodontic intervention in the early mixed dentition: a prospective controlled study on the effects of eruption guidance appliance. *Am J Orthod Dentofacial Orthop.* In press.
10. Keski-Nisula K, Lehto R, Lusa V, Keski-Nisula L, Varrela J. Occurrence of malocclusion and need of orthodontic treatment in early mixed dentition. *Am J Orthod Dentofacial Orthop.* 2003;124:631–638.
11. Bergersen EO. The eruption guidance myofunctional appliance: how it works, how to use it. *Funct Orthod.* 1984;1:28–35.
12. Keski-Nisula K, Keski-Nisula L, Mäkelä P, Mäki-Torkko T, Varrela J. Dentofacial features of children with distal occlusions, large overjets, and deep-bites in the early mixed dentition. *Am J Orthod Dentofacial Orthop.* 2006;130:292–299.
13. Methenitou S, Shein B, Ramanathan G, Bergersen EO. The prevention of overbite and overjet development in the 3 to 8 year old by controlled nighttime guidance of incisal eruption: a study of 43 individuals. *J Pedod.* 1990;14:218–230.
14. Janson GRP, Pereira ACJ, Bergersen EO, Henriques JFC, Pinzan A, de Almeida RR. Cephalometric evaluation of the eruption guidance appliance in Class II, division I treatment. *J Clin Orthod.* 1997;31:299–306.
15. Janson GRP, de Silva CCA, Bergersen EO, Henriques JFC, Pinzan A. Eruption guidance appliance effects in the treatment of Class II, division 1 malocclusions. *Am J Orthod Dentofacial Orthop.* 2000;117:119–129.
16. Janson GRP, de Souza JEP, de Freitas MR, Henriques JFC, Calvalcanti CT. Occlusal changes of Class II malocclusion treatment between Fränkel and the eruption guidance appliances. *Angle Orthod.* 2004;74:521–525.
17. Pancherz H. The Herbst appliance—its biologic effects and clinical use. *Am J Orthod.* 1985;87:1–20.
18. McNamara JA Jr, Bookstein FL, Shaughnessy TG. Skeletal and dental changes following functional regulator therapy on Class II patients. *Am J Orthod.* 1985;88:91–110.
19. McNamara JA Jr, Howe RP, Dischinger TG. A comparison of the Herbst and Fränkel appliances in the treatment of Class II malocclusions. *Am J Orthod Dentofacial Orthop.* 1990;98:134–144.
20. Mills C, McCulloch K. Treatment effects of the Twin-block appliance: a cephalometric study. *Am J Orthod Dentofacial Orthop.* 1998;114:15–24.
21. Toth LR, McNamara JA Jr. Treatment effects produced by the Twin-block appliance and the FR-2 appliance of Fränkel compared with an untreated Class II sample. *Am J Orthod Dentofacial Orthop.* 1999;116:597–609.
22. Janson GRP, Toruno LJA, Martins DR, Henriques JFC, de Freitas MR. Class II treatment effects of the Fränkel appliance. *Eur J Orthod.* 2003;25:301–309.
23. Baccetti T, Franchi L, Toth LR, McNamara JA Jr. Treatment timing for Twin-block therapy. *Am J Orthod Dentofacial Orthop.* 2000;118:159–170.
24. Faltin KJ, Faltin RM, Baccetti T, Franchi L, Ghiozzi B, McNamara JA Jr. Long-term effectiveness and treatment timing for Bionator therapy. *Angle Orthod.* 2003;73:221–230.
25. McNamara JA. Maxillary transverse deficiency. *Am J Orthod Dentofacial Orthop.* 2000;117:567–570.
26. You Zhi-Hao, Fishman L, Rosenblum R, Subtelny D. Dentoalveolar changes related to mandibular forward growth in untreated Class II persons. *Am J Orthod Dentofacial Orthop.* 2001;120:598–607.
27. Johnston L. Growing jaws for fun and profit: a modest proposal. In: McNamara JA Jr, Kelly KA, eds. *Treatment Timing: Orthodontics in Four Dimensions.* Craniofacial Growth

- Series, Vol. 36. Ann Arbor, MI: Department of Orthodontics and Pediatric Dentistry and the Center for Human Growth and Development, University of Michigan; 1999:13–24.
28. Wieslander L, Lagerström L. The effect of activator treatment on Class II malocclusion. *Am J Orthod.* 1979;75:20–26.
  29. Pancherz H, Hansen K. Occlusal changes during and after Herbst treatment: a cephalometric study. *Eur J Orthod.* 1986;8:215–228.
  30. Bishara SE, Ziaja R. Functional appliances: a review. *Am J Orthod Dentofacial Orthop.* 1989;95:250–258.
  31. Proffit WR. Treatment timing: effectiveness and efficacy. In: McNamara JA Jr, Kelly KA, eds. *Treatment Timing: Orthodontics in Four Dimensions.* Craniofacial Growth Series, Vol. 39. Ann Arbor, MI: Department of Orthodontics and Pediatric Dentistry and the Center for Human Growth and Development, University of Michigan; 2002:13–24.
  32. Bishara SE, Jacobsen JR, Vorhies B, Bayati P. Changes in dentofacial structures in untreated Class II division I and normal subjects: a longitudinal study. *Angle Orthod.* 1997; 67:55–66.
  33. Bishara SE, Hoppens BJ, Jakobsen JR, Kohout FJ. Changes in the molar relationship between the deciduous and permanent dentitions. *Am J Orthod Dentofacial Orthop.* 1988; 93:19–28.
  34. Feldmann I, Lundström F, Peck S. Occlusal changes from adolescence to adulthood in untreated patients with Class II Division I deepbite malocclusion. *Angle Orthod.* 1999;69: 33–38.
  35. Baccetti T, Franci L, McNamara JA Jr, Tollaro I. Early dentofacial features of Class II malocclusion: a longitudinal study from the deciduous through the mixed dentition. *Am J Orthod Dentofacial Orthop.* 1997;111:502–509.